Animal and Veterinary Science Department
University of Idaho
EMBRYOGENESIS AND SEXUAL DIFFERENTIATION
AVS 222 (Instructor: Dr. Amin Ahmadzadeh)
Chapter 4

I. DIFFERENTIATION: Process by which a primitive group of unspecialized cells develop a functional and specialized group of cells that provide a common function

A. Involves Formation of **Three Germ Layers** within a developing embryo:

1. Embryonic tissue, which forms all adult tissues and organs

B. Germ Layers formed during **gastrulation** (re-arrangement of the embryonic cells)

C. Three Germ Layers**: (Table 4-1)**

1. **Ectoderm:** In general, forms exterior tissues **(Figure 4-1)**

a. Skin, hair, sweat glands

b. Mammary glands

c. **Hypothalamus, Anterior/posterior Pituitary**

d. Part of the reproductive tract (male and female)

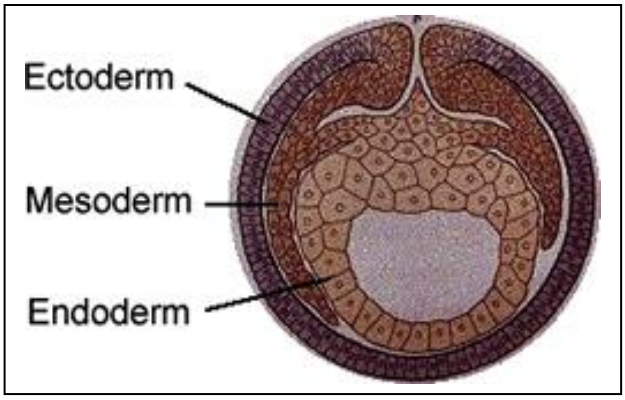

2. **Mesoderm**: in general, forms structural tissue **(Figure 4-1)**

a. Muscle, skeletal system, blood vessels

b. **Reproductive system**

-gonads, uterus, cervix, part of vagina, accessory sex glands

c. Renal system (urinary system)

d. Skeletal system

3. **Endoderm**: in general, form internal organs **(Figure 4-1)**

a. Digestive system, Liver, lungs

b. Majority of glands

II. SEXUAL DIFFERENTIATION AND DETERMINATION

A) Genetic differentiation

1. An individual's sex is genetically determined by the presence of a Y chromosome
2. Genetic differentiation takes place at fertilization when a sperm delivers either an X (female) or Y (male) chromosome to the oocyte
3. **SRY gene:** Sex determination gene located on the **Y chromosome**
   i. Causes the undifferentiated gonad to develop into the testis

4. SRY gene controls the expression of **Testis Determining Factor (TDF),** which is secreted by the **sex cords.**

6. **TDF** controls the pathway towards either male or female development.

B) Gonadal differentiation (Figure 4-5)

1. Development of primordial germ cells in the yolk sac (first 15% of gestation)
2. Migration of primordial germ cells from the yolk sac into the **genital ridge**
3. Genital ridge gives rise to **undifferentiated/bipotential gonad**
4. Genital ridge with stimulation of sex cords give rise to **renal system**
5. Development of the urinary system **(Figure 4-5)**
   i. **pronephros** (primitive kidney)
   ii. **mesonephros** (closely associated with the **undifferentiated gonad)**
   iii. **metanephros** (becomes the functional kidney)
6. Development reproductive tract
   a. **Mesonephric ducts -** Wolffian Ducts; MALE reproductive tract **(Figures 4-5 and 4-7)**
   b. **Paramesonepheric ducts -** Müllerian Ducts; FEMALE reproductive tract **(Figures 4-3, 4-5, and 4-7)**

REMEMBER! BOTH the mesonephric and paramesonephric ducts are present at the SAME TIME, called the SEXUALLY INDIFFERENT STAGE. The undifferentiated gonads thus need a signal to differentiate into either female or male gonads.

Male Gonadal Differentiation (See Figure 4-5; 4-6)

I. Presence of Y chromosome/ SRY gene
↓
II. Presence of **Testis Determining Factor (TDF)**
↓
III. Development of undifferentiated gonad to testes and Sertoli cells
↓
IV. Secretion of **Anti-Müllerian Hormone (AMH) by sertoli cells**
↓
V. Degeneration of Müllerian ducts (paramesonephric) and **development of Wolffian ducts** (mesonephric)
↓
VI. Differentiation of interstitial Leydig cells
↓
VII. Secretion of **testosterone from Leydig cells** and development of **male reproductive duct system**

7. Female Gonadal Differentiation (See Figure 4-6; 411 to 4-13)

I. **No** Y chromosome/ Absence of SRY gene
↓
II. **No** Testis Determining Factor (TDF)
↓
III. Development of **ovaries**
↓
IV. **No** Sertoli cells
↓

V. **Absence** of Anti-Müllerian Hormone (AMH)

VI. ↓

VII. Regression of Wolffian ducts and **differentiation of Müllerian ducts**

VIII. ↓

IX. Development of **female reproductive duct system**

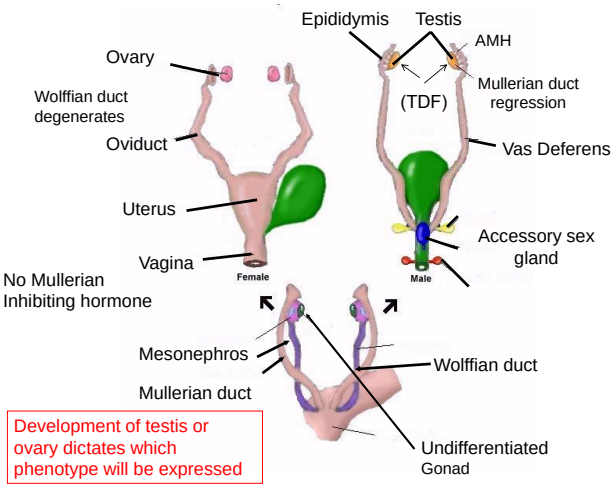

C) Hypothalamic/Brain Differentiation (Figure 6.1)

Pre-knowledge*:* The hypothalamic GnRH surge center is necessary for initiation of the estrous cycle and follicular ovulation in the female

A. Male Hypothalamic Differentiation (Defeminization of the Brain)

Pre-knowledge: Hypothalamic GnRH surge center is necessary for initiation of the estrous cycle and follicular ovulation in the female

I. Testosterone from the fetal testis **crosses the blood-brain barrier** and reaches the brain

↓

II. Testosterone is converted to estradiol by **aromatase enzyme** in the hypothalamus

↓

III. Regression of the hypothalamic GnRH surge center by estradiol

↓

IV. Defeminization of the hypothalamus (no surge center)

B. Female Hypothalmic Differentation (Feminization of the Brain)

FAQ: If synthesis of estradiol in the hypothalamus is responsible for defeminization of the surge center, why doesn't the female (with high levels of circulating estradiol) become "defeminized"?

I. **Estradio**l from fetal ovaries binds with a protein called **alpha-fetoprotein** (produced by the liver)

↓

II. Alpha-fetoprotein prevents estradiol from crossing blood brain barrier

↓

III. Estradiol **cannot** affect the hypothalamic surge center

↓

IV. Surge center retained in females

III. Testicular Descent (Figure 4-8)

A. Three phases

1. Growth and elongation of the body away from the stationary testes.
2. Rapid growth of the distal **gubernaculum**
    a. Rapid growth results in the testes being pulled from the region of the tenth thoracic vertebra to the inguinal ring
3. Shrinkage of the gubernaculum within the scrotum pulls the testes through the inguinal ring.
    a. Regression continues and gubernaculum situates the testes within the scrotum.

B. Growth and regression of the gubernaculum

1. **Testosterone** (from Leydig cells) and **insulin like-3 (Insl-3)** (also called **descendin**) synthesized by the fetal pancreas needed for gubernacular growth
2. Intra-abdominal pressure may play a larger role in the movement of the testes out of the abdomen and into the scrotum

What happens when the testes fail to descend?

1**. Cryptorchidism:** *Undescended testes or testis* ("Crypt" = hidden "Orchid" = testis)
    a. **Bilateral cryptorchid**: both testes retained in body cavity: Male is sterile
    b. **Unilateral cryptorchid**: one testis retained: Male is fertile-sub-fertile
2. Hormone production is NOT decreased in cryptorchid males
    a. Will exhibit secondary sex characteristics and normal reproductive behavior
3. Cryptorchidism is heritable-therefore cull
    a. It is possible to surgically or with pharmaceuticals lower the retained testis; however, it is most likely that fertility will be compromised
4. Descent of testes from the body cavity into the scrotum occurs by:
    a. mid-gestation (bull and ram)
    b. last quarter of gestation (boar)
    c. just before birth/ at birth (stallion)

Why are bilateral cryptorchids sterile?

Temperature regulation: The temperature requirements for normal spermatogenesis is specific. If you increase the temperature of the scrotum and the testes cannot lower to allow for cooling (thermoregulation) spermatogenesis is impaired (increased # of abnormal sperm=decreased fertility)

Freemartinism: ("free" = sterile "martin" = bovine)

- Common blood supply between twins during gestation
- Testosterone and AMH from male fetus influences female fetus
- Paramesonephric ducts in female do not develop correctly
- Results in **canalization** and a "blind" reproductive tract in the female

- Ovaries do not develop properly and do not secrete estradiol → secrete testosterone instead
- Often see male-like behavior in freemartin heifers

Why keep freemartin heifers in your herd?

Normally we should not, but it may useful for detecting estrus in other females due to male-like sexual behaviors!